

# A multidisciplinary approach to oral rehabilitation with osseointegrated implants in children and adolescents with multiple aplasia

B. Bergendal, T. Bergendal, A-L. Hallonsten, G. Koch, J. Kurol and S. Kvint

Institute for Postgraduate Dental Education, Jönköping, Sweden

**SUMMARY** Oral rehabilitation of children with extensive aplasia includes a number of dental considerations as well as attention to psychological and physical development. The well-documented results of the use of implants in adults have raised the question of the use of implants and the timing of this procedure in children and adolescents with multiple aplasia.

Eight-years' experience of a multidisciplinary approach to oral rehabilitation of children with extensive aplasia is described. Special emphasis is placed on early diagnosis, careful therapy planning, and co-ordination and timing of different parts of the therapy. The specific considerations from the point of view of paediatric dentists, orthodontists, oral surgeons, and prosthodontists are presented. A system for integrating all these aspects and knowledge will be a guarantee for high professional standards and a successful outcome. To exemplify the multidisciplinary approach, three treated cases are presented.

## Introduction

Extensive aplasia can in a growing individual be a disabling condition which has to be met with special considerations concerning psychological and physical development. Independent of the care strategy, careful therapy planning and co-ordination of different parts of the therapy are of utmost importance in order to achieve the best possible result with the least distress and suffering for the growing individual (Bergendal *et al.*, 1991; Oesterle *et al.*, 1993).

The care of children and adolescents with cleft lip and palate has a long tradition of multidisciplinary co-ordination from birth to adulthood at specialist centres. Similar systematic planning for dental care of children and adolescents with extensive aplasia has not been reported earlier.

Well-documented experience of the use of oral implants in adults with total loss of teeth (Brånemark *et al.*, 1985) has led to identification of further indications for the method. Among other potential candidates, children and teenagers with multiple aplasia have come into focus. The question has been raised whether oral implants can offer a better alternative to

conventional prosthetic and/or orthodontic therapy with good long-term results.

This paper will present 8 years' experience of a multidisciplinary approach to oral rehabilitation with osseointegrated implants in children and adolescents with multiple aplasia.

## *Multiple aplasia: epidemiological aspects*

The prevalence of the congenital lack of six or more teeth, excluding the third molars, has been reported to vary between 0.2 and 0.07 per cent (for review see Schalk-van der Weide, 1992). In this recent Dutch study, the prevalence of aplasia of six or more permanent teeth was found to be 0.08 per cent, corresponding to a ratio of 1:1250. Even though multiple aplasia is rare, for the individual affected it represents a severe condition. A system for early identification therefore is an urgent prerequisite for optimal professional management.

In a survey performed in the county of Jönköping, Sweden, comprising all individuals younger than 20 years with aplasia of eight or more permanent teeth (third molars excluded), 27 individuals were identified. This corresponds to a prevalence of 0.06 per cent. Orthopantomograms and study casts were collected. Of the

27 patients, 15 were girls and 12 boys, aged 8–19 years (mean 14.4 years, SD 3.20). Altogether they had 315 missing teeth in both jaws, with a mean of 11.7 (SD 4.20, range 8–22 teeth). The number and distribution of missing permanent teeth in the upper and lower jaw are shown in Fig. 1. In this group of children with multiple aplasia one-third had other diagnosed disabilities: two had ectodermal dysplasia, five had Down's syndrome and two had mild mental retardation.

In order to illustrate the location of the aplasias in the jaws and adjust for the varying developmental age of the children schematic drawings were made from the available orthopantomograms. Some examples are presented in Fig. 2. Aplasia occurred in all teeth except the upper central incisors in this material. In 23 children (85 per cent) one incisor or more was missing. We therefore strongly recommend that in children who at the age of 8 years are missing one incisor, an extended radiographic examination (e.g. orthopantomogram) should be carried out to facilitate early diagnosis. This is also advisable in their siblings since heredity is one of the most important aetiological factors presented in the literature (Schalk-van der Weide, 1992).

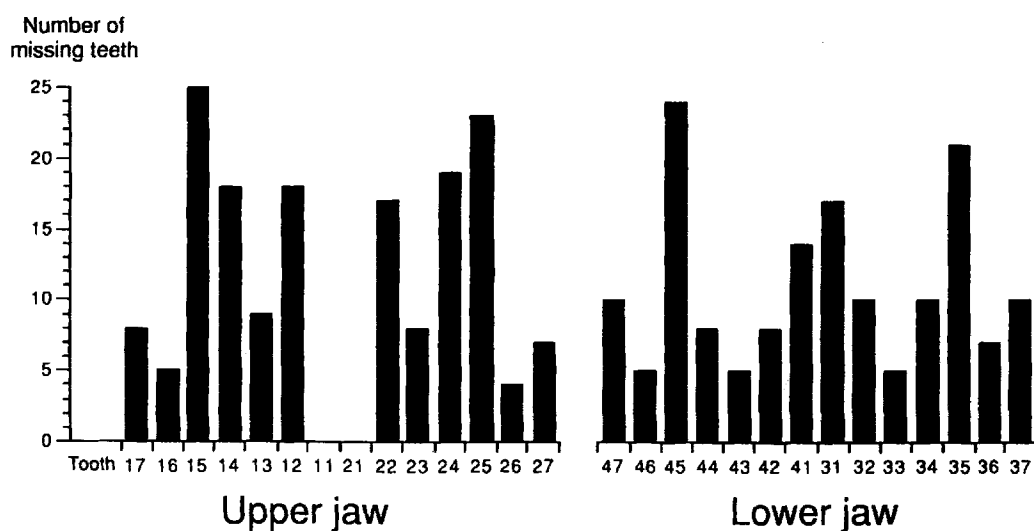
From the location of the aplasias in the diagrams, it was also found that in 14 jaws in 10 children there were areas of multiple aplasia

where future implant therapy could be suitable, not taking into account the quality or quantity of bone or the outcome of future growth and development or preprosthetic orthodontic treatment.

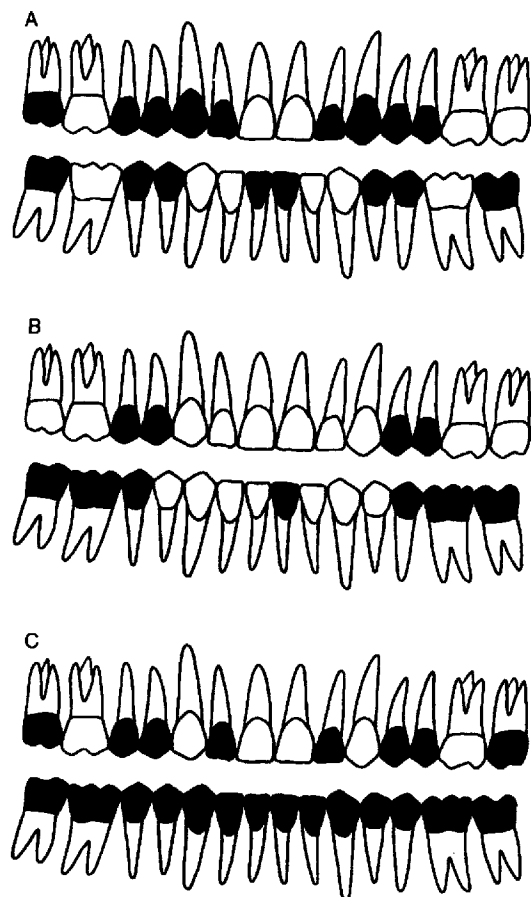
#### *The multidisciplinary group*

In 1985, a multidisciplinary group was formed with representatives from the dental specialties orthodontics, paediatric dentistry, oral surgery, prosthodontics and a consultant oral radiologist. The group was formed with the objective of giving optimal and rational dental care to children and adolescents with multiple aplasia and in need of long-lasting and extensive dental rehabilitation. Children with multiple aplasia are referred to the group at 8–10 years of age, when the diagnosis has been made in the Public Dental Service. When the patient is registered, thorough documentation including radiographs, study casts, colour slides and clinical examination by a specialist in orthodontics or paediatric dentistry is performed. In most of the cases, the group also has the opportunity to examine the child clinically. This provides an opportunity to discuss the objectives of the treatment planning with the patient and his or her family.

Normally, a preliminary long-term treatment plan is established at the age of 8–10 years, as well as a detailed plan for the coming years. A



**Figure 1** Number and distribution of missing permanent teeth (upper jaw 161, lower jaw 154) in 27 individuals. Inclusion criterion: aplasia of eight or more permanent teeth, third molars excluded.



**Figure 2** Schematic chart of dentitions where aplasias are marked in black. These three diagram correspond to the cases presented in this paper (Figs 3–5).

thorough analysis of alternative modes of treatment is made, taking into account, for example preventive, orthodontic, prosthodontic and surgical aspects. In some instances the child needs a referral for a medical examination and/or clinical genetic consultation.

In our experience, there are a number of problems which have to be discussed and handled in the process of therapy planning for these children during several years of development and growth. Some of the most common issues discussed at the group meetings are presented in Table 1.

The group meets four or five times per year and over the years some 80 patients have been discussed. The treatment of the patient is closely followed and presented in the group. If necessary, the treatment plan is revised. The basic

**Table 1** Examples of common issues discussed in the multidisciplinary group.

- 
- \*The reaction of the family at the time of diagnosis
  - \*Early considerations on permanent therapy
  - \*Aesthetic considerations
  - \*Optimal preventive measures
  - \*Facial growth pattern
  - \*Other tooth developmental disturbances such as reduced tooth size, hypomineralization of teeth and eruption disturbances
  - \*Need for interceptive orthodontic care
  - \*Control of the vertical dimension
  - \*Dento-alveolar growth
  - \*Overeruption in areas where aplasia is present in the opposite jaw
  - \*Extraction or preservation of primary teeth
  - \*Space maintenance
  - \*Optimal placement of existing teeth
  - \*Intermediate appliances to replace missing teeth
  - \*Possibility of autogenous transplantation of teeth
  - \*Measures to preserve the alveolar ridge optimally for fixture installation
  - \*Analysis of the quantity and quality of bone in the edentulous areas
  - \*Implant therapy
- 

strategy for planning and treatment of children with multiple aplasia at different ages is shown in Table 2. The most important factor in handling these patients is, in our opinion, early diagnosis and continuous co-ordination of the different steps in the preliminary therapy plan with respect to growth and development.

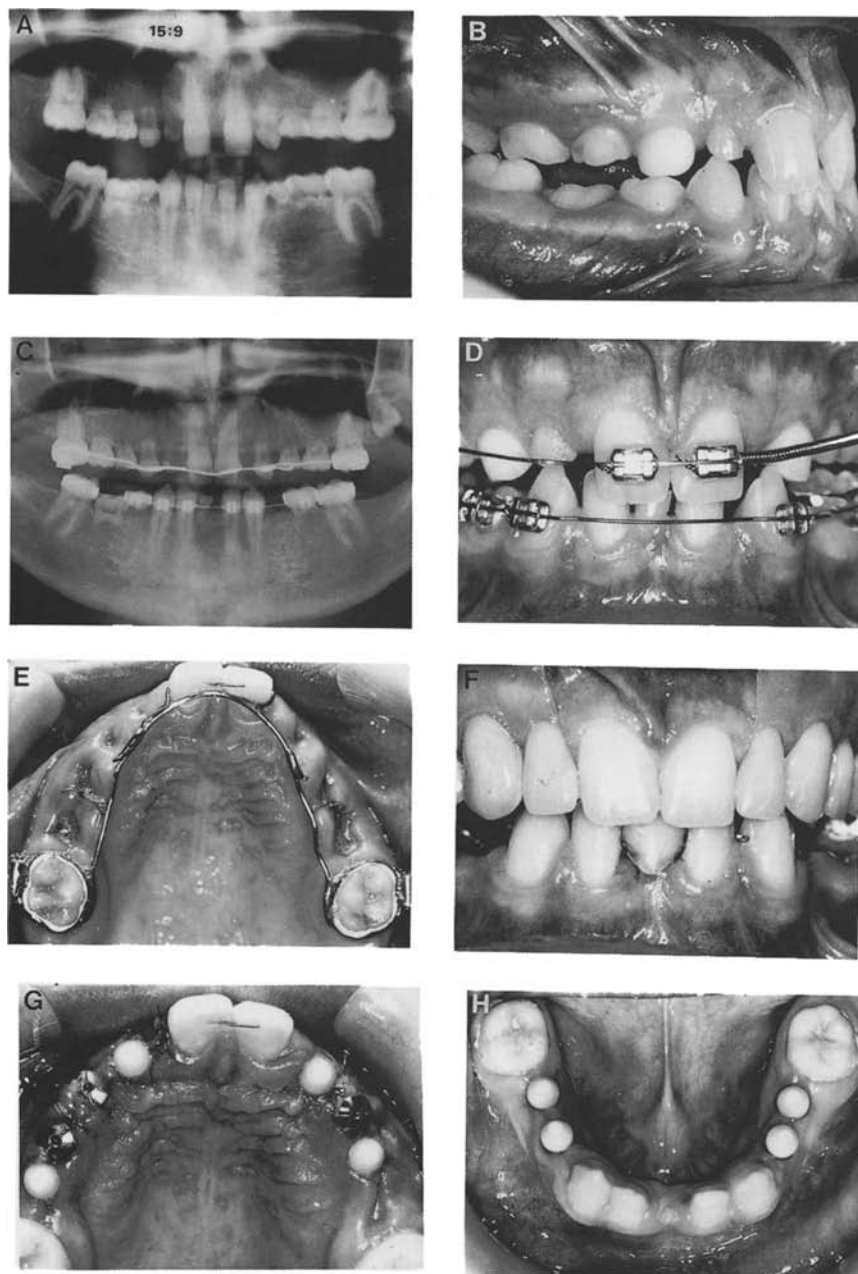
By following this strategy a number of advantages can be achieved, such as:

1. Continuous information and support to the child and family
2. Comprehensive view of oral rehabilitation
3. Continuity and co-ordination of planning
4. Shared responsibility for decisions on therapy
5. Optimal utilization of competence
6. Increased experience within the group.

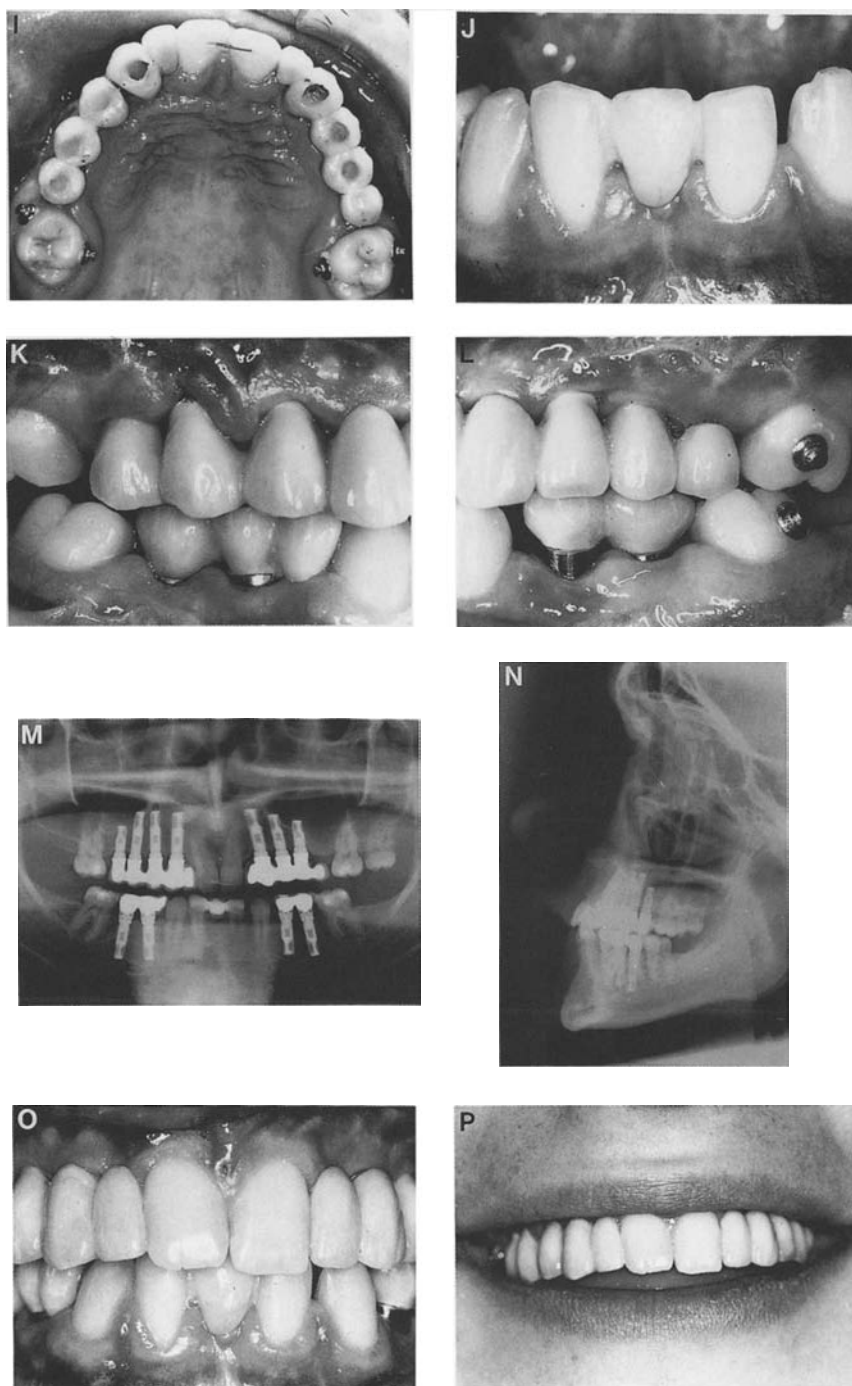
This treatment strategy based on a multidisciplinary approach, means that all decisions have the potential of using the full competence of the different specialists. All specialities thus have an impact on the process by contributing their specific views and knowledge on rehabilitation. Three treated cases are presented in Figs 3–5.

### Paedodontic aspects

Aplasia involving several teeth should be considered a disabling condition. Disabilities give



**Figure 3** (A) Orthopantomogram from a 16-year-old boy with multiple aplasia who has not requested treatment until now because of dentophobia. Permanent teeth 16, 11, 21, 26, 28, 36, 33, 32, 42, 43, 46. (B) Corresponding clinical situation. (C) Orthopantomogram after preprosthetic orthodontic treatment. (D) Corresponding clinical situation. (E) Upper jaw after extraction of deciduous teeth. (F) The boy was immediately fitted with a partial temporary removable prosthesis. (G) After completed installation of implants in the upper and (H) lower jaws ready for prosthetic treatment at the age of 19 years 6 months.



**Figure 3 (cont)** (I) Occlusal view of metal-ceramic fixed prostheses. Teeth 11, 21 with permanent retention. (J) In the lower jaw there is an all ceramic front prosthesis extending from 32 to 42. (K) Lateral views of implant-supported metal-ceramic prostheses. Note the increased vertical dimension leaving the molars without occlusal contacts. (L) The orthodontic vertical correction of the molars is performed with light elastics from the buttons. (M–N) Orthopantomogram and radiographic lateral head film after treatment. (O–P) Frontal appearance of implant-supported fixed prosthesis at the age of 20 years. (O) Intra-oral view and (P) Smile line.



**Table 2** Flow chart of clinical considerations and decisions made from early diagnosis to end of treatment for children with multiple aplasia.

Age (years)	Clinical consideration	Treatment planning	Measures and treatment
8	Children with any missing incisors are further examined radiographically as well as siblings or children of parents with extensive aplasia Type of occlusion and facial growth pattern Orthodontic consultation	Prophylactic measures	Information Prophylaxis Information on preliminary treatment plan
10–11	Check of alveolar growth and eruption of maxillary canines	Start discussion of the type of definite prosthetic rehabilitation	Orthodontic treatment with correct positioning of incisors, treatment of deep bite, control of tooth eruption. Composite recontouring of anterior teeth
12–14	Alveolar and facial growth and development	Discussion on extraction of primary teeth Consider autotransplantation Position of future abutment teeth in relation to edentulous areas	Extensive orthodontic treatment, often fixed appliances Retention of orthodontic treatment Temporary prosthetic appliances
14	Bone mass and bone quality in edentulous areas	Possibility of installing implants	Implant surgery and/or prosthetic therapy
18–19	Tomography Completed facial growth?	Decision on prosthetic therapy	

rise to emotions among children, parents and care-providers which, in combination with limited knowledge among the care-providers about what to do and when, results in a risk that misleading and scanty information is given to the parents and the child. This can lead to misunderstandings and anxiety. Furthermore, it is a well-known fact that information that gives rise to emotions has to be repeated several times since psychological factors limit the message received by, for example the parents.

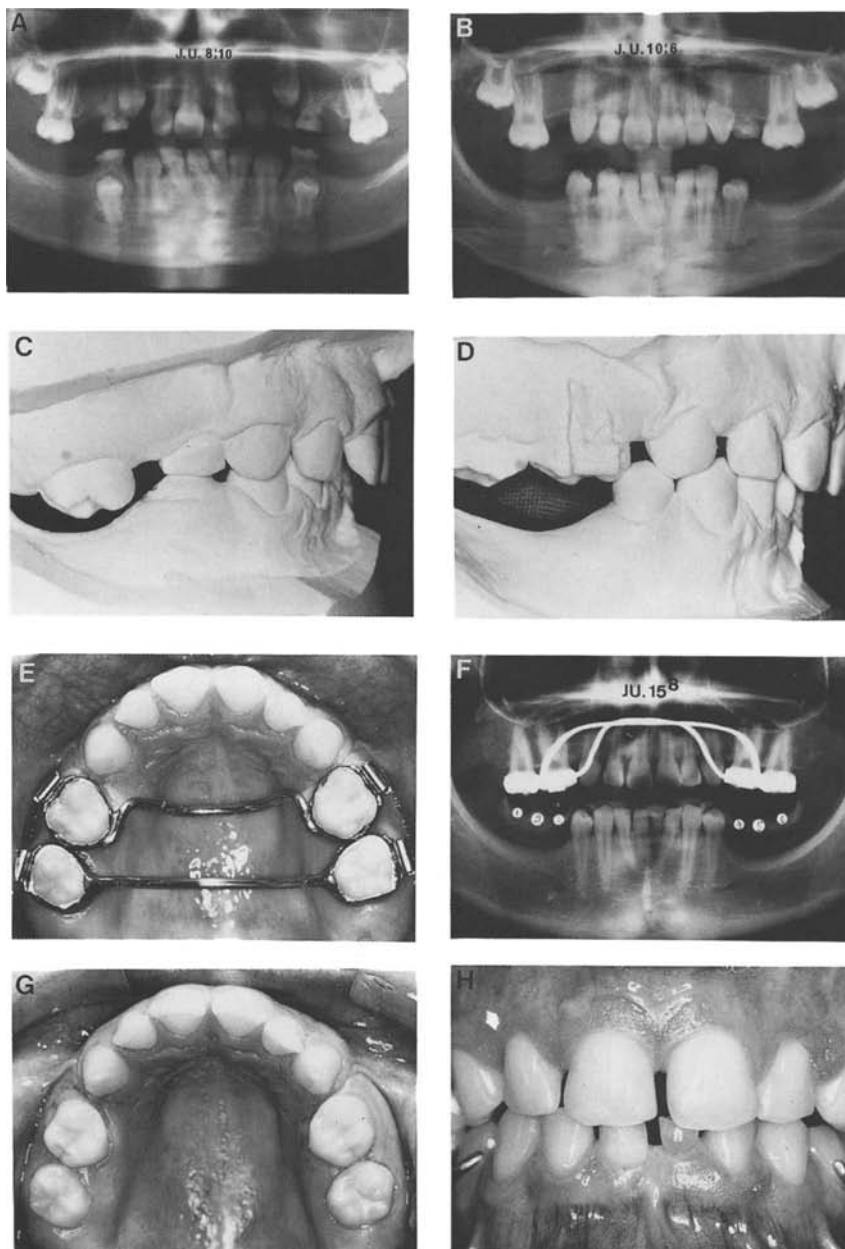
Little is known about how children react to the situation of many missing teeth. In early childhood the reaction and support from the family is, of course, of utmost importance. From studies in children with disabilities, it has been found that at about the age of nine the child can understand that he is and will remain different from other children (Lagerheim, 1983). This knowledge may in disabled children give rise to a period of depression. It is most likely that the same can happen in children with severe aplasia. Later on in preadolescence, children with disabilities are confronted with thoughts of attractiveness in the group of teenagers they meet. Temporary rehabilitation with good aesthetics is therefore important. This

could (without restricting future therapy) be accomplished by recontouring anterior teeth with composite resin materials.

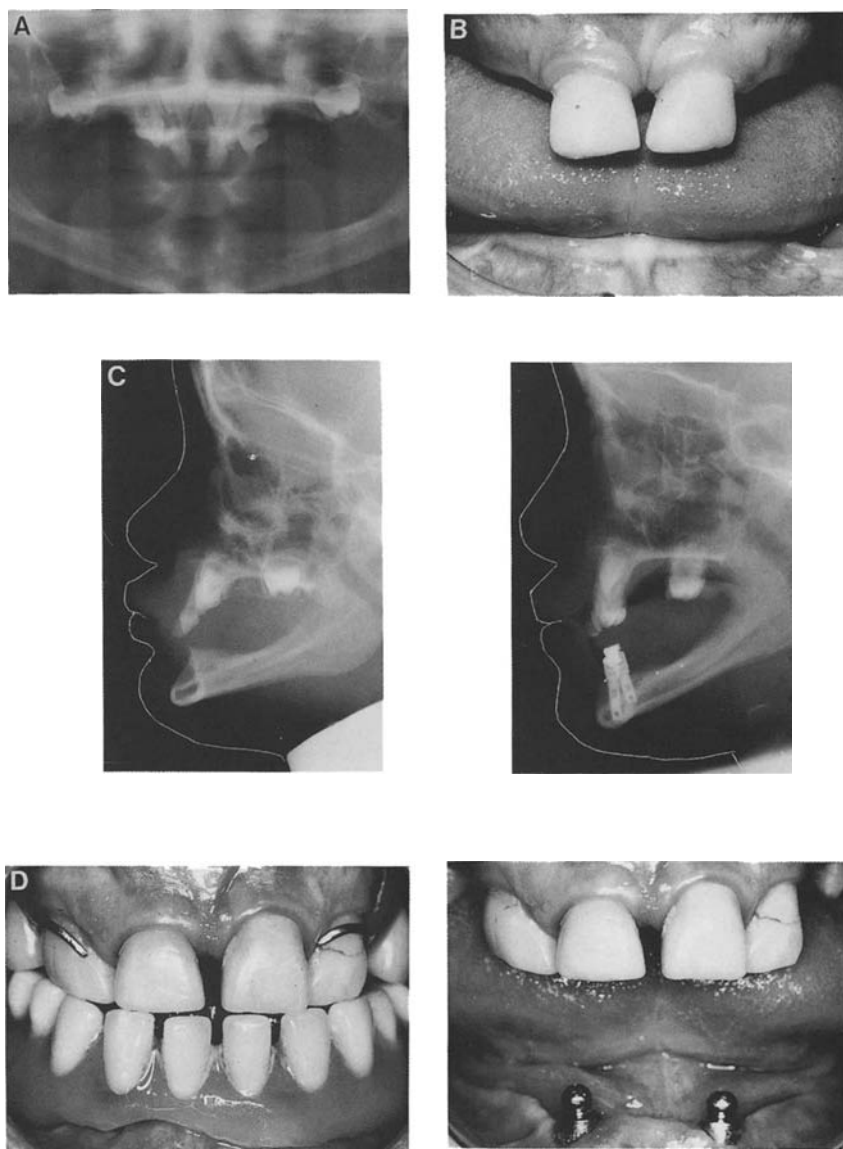
Children with aplasia have to be recorded as children at risk of developing dental disease. Because of the minimal amount of dental material available, every sign of caries or periodontal disease must be prevented. Individually adapted preventive dental care programmes therefore have to be designed for each child with aplasia, depending on the degree of aplasia, psychological developmental stage and possible incipient signs of dental disease. When dental care is undertaken in children with aplasia, careful information must precede the intervention and painless dentistry is essential.

### Orthodontic considerations

Growth, and especially vertical growth of the alveolar processes, is related to tooth eruption. In children with aplasia in lateral segments, a decreased height of the alveolar processes is often found. The shape of the palatal vault is often flatter. In cases with extensive aplasia, the lower face height is often smaller than normal and a deep bite is commonly found. This may give the impression of a squarer face.



**Figure 4** (A) Orthopantomogram of a girl at the age of 8 years 10 months. All premolars in the upper jaw and all permanent molars in the lower jaw are missing, together with the second lower premolars. (B) In order to initiate a mesial movement of the molars, the deciduous upper second molars were removed at 8 years 10 months. Note the favourable space closure. (C) During mesial movement, the molars overerupt due to lack of opposing molars, 9 years 8 months of age. (D) At 16 years of age the molars have been intruded and further mesially moved by placement of transpalatal arches 4–5 mm away from the palatal mucosa. The tongue function has moved the molars. (E) Intra-oral view of the orthodontic appliances. Note that the space after both the first and second deciduous molars is now completely closed. (F) Orthopantomogram showing good axial inclination of the moved molars. In the lower jaw an acrylic plate with steel balls is placed for preliminary planning of implant sites with the use of computed tomography. (G) Occlusal view of the upper dental arch at the end of active orthodontic treatment at 16 years of age. (H) Frontal view with good vertical dimension. Note attrition of lower deciduous incisor. In lateral segments a removable partial prosthesis now controls the vertical height and hinders overeruption of the upper molars. Implants will be placed in the lower molar region at the end of the growth period at about the age of 18–20 years.



**Figure 5** (A) Orthopantomogram at 3 years of age. Visible permanent tooth germs are 16, 11, 21 and 26. Total aplasia in the lower jaw. (B) Corresponding clinical situation. (C) Profile radiograph at 3 years of age (left) and at 9 years of age (right). Note the increased vertical dimension due to the prosthetic treatment in the lower jaw. (D) The actual clinical situation 8 years after the start of prosthetic treatment. Frontal view with (left) and without (right) prosthesis.

Examples of orthodontic problems in cases of multiple aplasia are listed in Table 3. Children with aplasia of more than four permanent teeth on average show maxillary retrognathism and anterior rotation of the mandible (Sarnäs and Rune, 1983) and smaller mandibular plane inclination and gonial angle (Nodal *et al.*, 1994). In cases with aplasia of lower incisors, the

primary incisors sometimes already show marked attrition at the age of seven or eight. The maxillary permanent incisors are often more vertically positioned and tend to over-erupt. One contributing factor may be that the mandibular incisors are retruded (Roald *et al.*, 1982). Spacing and diastemas are commonly found since aplasia patients often have generally



**Table 3** Possible orthodontic and prosthodontic problems in patients with extensive aplasia.

---

*Decreased vertical growth in alveolar processes
*Deep bite
*Low anterior face height
*Attrition of persisting lower primary incisors
*Overeruption of maxillary incisors
*Generally smaller permanent teeth
*Root resorption of primary teeth even when the permanent successor is missing
*Risk of large spaces when primary teeth are lost
*Wrong position of permanent abutment teeth
*Possibility of ankylosis and infraocclusion of persisting primary molars
*Overeruption of permanent molars
*Difficult positioning of the present/remaining permanent teeth

---

smaller permanent teeth (Rune and Sarnäs, 1974; Brook, 1984; Shalk-van der Weide, 1992). However, other investigators have not found this association (Wisth *et al.*, 1974). Root resorption of primary teeth with the successors missing occurs and may be unpredictably rapid and unfortunate. If this occurs late, at 13–15 years of age, large spaces are left for prosthetic rehabilitation. The orthodontic space closure or reduction of the space is also more difficult in older individuals. In adolescents, the spontaneous mesial drift is minimal and of minor clinical importance. Primary molars with aplasia of successors may become ankylosed with an increasing degree of infraocclusion. Besides underdevelopment of the surrounding bone, the neighbouring teeth may tip and cause an occlusal disturbance (Kurol and Thilander, 1984).

In cases where lower molars are missing, the maxillary molars may overerupt if not hindered by the function of the tongue. Eruption disturbances are more common in subjects with aplasia (Svinhufvud *et al.*, 1988; Bjerklin *et al.*, 1992).

In order to assess the cessation of the more active growth period, measurements of body height should be started early. The facial growth pattern should also preferably be analysed during the initial treatment planning.

Aplasia cases present potential problems during orthodontic treatment. With a decreased number of permanent teeth, the anchorage may not be as strong as usual and the forces should therefore be adjusted to the situation. The space closure may also be slower than normal, with residual spaces as a result. Possible explanations may be less bone mass, generally smaller teeth

and weaker anchor units, all of which make space closure more difficult.

### Surgical considerations

Surgical treatment of these patients with extensive aplasia may include different techniques, e.g. autotransplantation, implants and orthognathic surgery. Autotransplantation could be used with a good prognosis where the aplasia is mainly located in one jaw and teeth can be used from the other jaw, for instance in patients with asymmetrical aplasia. Orthognathic surgery aims at good facial proportions and normal occlusion.

Implants may be the method of choice in patients with multiple aplasia (Higuchi, 1992). The surgeon must then try to answer the following questions: What are the demands for space, both vertically and horizontally? Is it possible to place the implants in a proper position from a prosthetic point of view? When is the proper time for installation? Is there sufficient bone of good quality for installation of the implants?

The Bränemark system (Bränemark *et al.*, 1985) has been used with good results for more than 20 years (Adell *et al.*, 1990). The implant used has an outer diameter of 3.75 mm. With a centre-to-centre distance of 6 mm, the space between two neighbouring teeth should be at least 14 mm for two implants and 21 mm for three. These distances normally correspond well with the centre-to-centre distance of the teeth. However, the width of the teeth is often reduced in children with aplasia. In the vertical dimension the prosthetic components require at least 7 mm between the head of the implants and the opposing occlusal surface. The distance between two opposite implants should thus be at least 15 mm in the vertical dimension.

The position of the implants determines the result of the prosthetic treatment, functionally and aesthetically. Meticulous planning of the location of the different implants together with the prosthodontist is necessary. A removable guiding plate will facilitate correct location of the implants during surgery.

The appropriate age for installation of implants in children and adults has been discussed. It is known from experience that implants will react as an ankylosed tooth when installed before the growth of the alveolar process has ceased (Ödman *et al.*, 1988; Thilander *et al.*,

1992; Ledermann *et al.*, 1993). Our opinion is that treatment with implants can be carried out at the very earliest when growth is almost complete. In rare cases of total aplasia, as in ectodermal dysplasia, treatment with implants could be advocated in childhood (Bergendal *et al.*, 1991, Oesterle *et al.*, 1993).

The surgeon must ensure that there is sufficient bone of suitable quality at the implant sites. Anatomical structures such as the maxillary sinus and the mandibular canal constitute borders which cannot be exceeded without risk, with today's existing methods. There are several different radiological methods for investigating these relationships (Hollender, 1992).

### Prosthetic considerations

When treating children and adolescents the same prosthetic materials and methods are used as when treating adults, but therapy planning as well as the actual treatment must be adapted to the young and growing individual.

The overall strategy should be to avoid prosthetic treatment as the final therapy by maximum utilization of growth-adapted measures. In cases where prosthetic therapy is mandatory, the objective should be to provide the patient with temporary appliances that meet aesthetic and functional demands throughout the period of growth. These should be designed according to established principles in order to avoid unnecessary tissue damage (Hedegård, 1965).

The role of the prosthodontist in the multidisciplinary group is mainly to take responsibility for the following areas of concern:

1. Early consideration of final therapy
2. Proper placement of abutment teeth
3. Aesthetic considerations
4. Temporary prosthetic therapy.

What is to be considered permanent therapy when the time perspective is a life-span is an open question. After completion of orthodontic therapy the patients are very often anxious to have their teeth treated permanently once and for all. When the prosthodontist has met the patient as a child and participated in the treatment planning, it is easier to explain to the patient and his or her family that in order to provide the optimal treatment certain measures are postponed until the patient is grown up.

In many cases, composite-retained onlay

bridges can serve well as long-term temporary treatment, especially in anterior regions. Good long-term results have been reported for Maryland bridges (Creugers *et al.*, 1992; Barrach and Bretz, 1993). If an alternative therapy is planned within a few years, a Rochette bridge is preferable since it is easier to remove. Removable partial dentures with a cast framework in cobalt-chromium, designed in accordance with proper requirements of rigidity and stability, can also serve well in teenagers and young adults (Koch and Olgart, 1979).

Preparation of teeth in young individuals should be avoided due to the risk of damage to the pulp and the short length of the clinical crowns. If artificial crowns are made in young patients they are often overcontoured, with an unsatisfactory aesthetic result, and will soon require revision. Short clinical crowns always jeopardize retention and the possibilities of meeting the dimensional requirements of fixed bridges are often limited (Roberts, 1970). With new adhesive techniques it is possible to restore single teeth with ceramic onlay crowns with only minor preparation. Such therapy could be performed on aesthetic indications in young patients also.

Our knowledge of the long-term results of treatment with osseointegrated implants in children and adolescents is as yet limited. Many aspects of treatment should be considered before such treatment is given to young patients, because of its irreversible character. In most cases, acceptable alternative treatment can be performed until the patient is grown up and can participate in the decisions and fully understand the phases of this complicated treatment. A majority of children in our country today lack experience of dental treatment since they are free of caries. This must be taken into account when all kinds of operative dentistry are performed, to ensure that optimal analgesia is given.

Irrespective of which prosthetic therapy will be the final one chosen, the requirements of space for teeth to be replaced for an optimal aesthetic result are almost the same. If there is uncertainty at the time of orthodontic treatment as to which type of prosthesis will be made later, it is advisable to create enough space in the mesio-distal as well as the vertical dimension for any treatment modality. If this is not possible it will affect the choice of treatment.

## Conclusions and clinical recommendations

The rehabilitation of children with multiple aplasia involves many phases, from diagnosis to treatment planning and the performance of the treatment itself. Many aspects of dentistry are involved, necessitating utilization of the general practitioner's skills together with contributions from different specialist disciplines. Our accumulated experience over the last 8 years has led to a multidisciplinary treatment approach which is illustrated in Table 2. Beside the potential for optimal treatment planning, the co-operation of specialists in the multidisciplinary group also has other significant advantages.

## Address for correspondence

Dr Juri Kurol  
Department of Orthodontics  
Institute for Postgraduate Dental Education  
Klubbhusgatan 15  
S-553 03 Jönköping  
Sweden

## References

- Adell R, Eriksson B, Lekholm U, Brånemark P-I, Jemt T 1990 A long-term follow-up study of osseointegrated implants in the treatment of totally edentulous jaws. *International Journal of Oral and Maxillofacial Implants* 5: 347-359
- Barrach G, Bretz W A 1993 A long-term prospective study of the etched-cast restoration. *The International Journal of Prosthodontics* 6: 428-434
- Bergendal T, Eckerdal O, Hallonsten A-L, Koch G, Kurol J, Kvint S 1991 Osseointegrated implants in the oral habilitation of a boy with ectodermal dysplasia: a case report. *International Dental Journal* 41: 149-156
- Bjerklin K, Kurol J, Valentin J 1992 Ectopic eruption of maxillary first permanent molars and association with other tooth and developmental disturbances. *European Journal of Orthodontics* 14: 369-375
- Brånemark P I, Zarb G, Albrektsson T (eds) 1985 *Tissue-integrated prostheses—osseo-integration in clinical dentistry*. Quintessence Publishing Co., Berlin
- Brook A H 1984 A unifying aetiological explanation for anomalies of human tooth number and size. *Archives of Oral Biology* 29: 373-378
- Creugers N H J, Käyser A F, Vant Hof M A 1992 A seven-and-a-half-year survival study of resin-bonded bridges. *Journal of Dental Research* 11: 1822-1825
- Hedegård B 1965 The traumatised front tooth. Some prosthetic aspects of therapeutic procedures. *Transactions of the European Orthodontic Society* pp 347-351
- Higuchi K 1992 Hypodontia and oligodontia. In: Worthington P, Brånemark P I (eds). *Advanced osseointegration surgery. Application in the maxillofacial region*. Quintessence Publishing Co, Berlin, pp 248-25
- Hollender L 1992 Radiographic examination of endosseous implants in the jaws. In: Worthington P, Brånemark P I (eds). *Advanced osseointegration surgery. Application in the maxillofacial region*. Quintessence Publishing Co., Berlin, pp 80-93
- Koch G, Olgart K 1979 Behandling vid aplasi hos barn och ungdom. In: *Odontologi-79*, Munksgaard, Copenhagen, pp 139-153
- Kurol J, Thilander B 1984 Infraocclusion of primary molars with aplasia of the permanent successor: a longitudinal study. *Angle Orthodontist* 54: 283-294
- Lagerheim B 1983 Why me? – A depressive crisis at the age of nine in handicapped children. In: Gyllensvard A, Lauren K (eds) *Psychosomatic diseases in childhood*. Sven Jerring Foundation, Stockholm
- Ledermann P D, Hassell T M, Hefti A F 1993 Osseointegrated dental implants as alternative therapy to bridge construction or orthodontics in young patients: seven years of clinical experience. *Pediatric Dentistry* 15: 327-333
- Nodal M, Kjær I, Solow B 1994 Craniofacial morphology in patients with multiple congenitally missing permanent teeth. *European Journal of Orthodontics* 16: 104-109
- Ödman J, Lekholm U, Jemt T, Brånemark P I, Thilander B 1988 Osseointegrated titanium implants: a new approach in orthodontic treatment. *European Journal of Orthodontics* 10: 98-105
- Oesterle L J, Cronin R J, Ranly D M 1993 Maxillary implants and the growing patient. *International Journal of Oral and Maxillofacial Implants* 8: 377-38
- Roald K L, Wisth P J, Bøe O E 1982 Changes in craniofacial morphology of individuals with hypodontia between the ages 9 and 16. *Acta Odontologica Scandinavica* 40: 65-74
- Roberts D H 1970 The relationship between age and the failure rate of bridge prostheses. *British Dental Journal* 128: 175-177
- Rune B, Sarnäs K V 1974 Tooth size and tooth formation in children with advanced hypodontia. *Angle Orthodontist* 44: 316-321
- Sarnäs K V, Rune B 1983 The facial profile in advanced hypodontia: a mixed longitudinal study of 141 children. *European Journal of Orthodontics* 5: 133-143
- Schalk-van der Weide Y 1992 Oligodontia. A clinical radiographic and genetic evaluation. Thesis, University of Utrecht
- Svinhufvud E, Myllärniemi S, Norio R 1988 Dominant inheritance of tooth malpositions and their association to hypodontia. *Clinical Genetics* 34: 373-381
- Thilander B, Ödman J, Gröndahl K, Lekholm U 1992 Aspects on osseointegrated implants inserted in growing jaws: a biometric and radiographic study in the young pig. *European Journal of Orthodontics* 14: 99-109
- Wisth P J, Thunold K, Bøe O E 1974 Frequency of hypodontia in relation to tooth size and dental arch width. *Acta Odontologica Scandinavica* 32: 201-206